

# OCULAR

## *Infection & Inflammation*

### *Herpetic Keratitis*

A continuing education newsletter for physicians, pharmacists, and nurses  
interested in infection & inflammation of the eye

#### *Faculty*

Charles B. Slonim, MD, FACS

Clinical Professor of Ophthalmology, USF Health


Herbert E. Kaufman, MD

Boyd Professor of Ophthalmology & Pharmacology & Experimental Therapeutics

Louisiana State University Medical Center School of Medicine

Jointly sponsored by





**Objectives**

At the conclusion of this activity, participants should be able to:

- Recognize symptoms of herpetic keratitis
- Perform appropriate clinical test to correctly diagnose herpetic keratitis

- Compare & contrast risks and precautions of treatments for herpetic keratitis
- Review evidence-based rationale behind current treatments for herpetic keratitis

**Disclosure of Relevant Financial Relationships with Commercial Interests**

USF Health endorses the standards of the ACCME that requires everyone in a position to control the content of a CME activity to disclose all financial relationships with commercial interests that are related to the content of the CME activity. CME activities must be balanced, independent of commercial bias and promote improvements or quality in healthcare. All recommendations involving clinical medicine must be based on evidence accepted within the medical profession.

include receiving a salary, royalty, intellectual property rights, consulting fee, honoraria, stocks or other financial benefits.

USF Health will identify, review and resolve all conflicts of interest that speakers, authors or planners disclose prior to an educational activity being delivered to learners. Disclosure of a relationship is not intended to suggest or condone bias in any presentation but is made to provide participants with information that might be of potential importance to their evaluation of a presentation.

A conflict of interest is created when individuals in a position to control the content of CME have a relevant financial relationship with a commercial interest which therefore may bias his/her opinion and teaching. This may

Relevant financial relationships exist between the following individuals and commercial interests:

**Faculty/Disclosures**

**Faculty/Staff**

Charles Slonim, MD, FACS

**Disclosure/Affiliation**

Bausch & Lomb, Santen, Meda,  
Johnson & Johnson, Sirion Therapeutics  
Sirion Therapeutics, ATON  
None/USF Eye Institute  
None/J. Haley Veterans Administration Hospital  
None  
None/USF Health  
None/USF Health  
None/Focus-ED

**Relationship**

Consultant, Speakers Bureau  
  
Consultant  
Reviewer  
Reviewer  
Author  
CME Coordinator  
CME Coordinator  
Project Manager

Herbert Kaufman, MD  
Linda Nakanishi, MD  
Linda W. Kam, PharmD  
Rebecca Aquino  
Betty Danzi  
Vicky Fortugno-Oliver  
Susan Easter, MS, CAE

**Accreditation**

**Target Audience:**

General ophthalmologists  
Cornea specialists  
Pharmacists  
Nurses



**Physicians:**

This activity has been planned and implemented in accordance with the Essential Areas and Policies of the Accreditation Council for Continuing Medical Education (ACCME) through the joint sponsorship of USF Health and Focus-ED. USF Health is accredited by the ACCME to provide continuing medical education for physicians.

of continuing nursing education by the American Nurses Credentialing Center's Commission on Accreditation. This activity is for 1.5 contact hours.

**Estimated Time:**

This activity will take 90 minutes to complete. Successful completion is defined as a score of 80%.

**Fees:**

No fee will be charged for this activity.

**CE credit:**

To claim CE credit, individuals must complete Ocular Infection & Inflammation, Vol. 1, Issue 1, Herpetic Keratitis Post Test, and Program Evaluation Form. Mail or fax these and the CE Request Form to the address below postmarked by October 31, 2010 to:

Attn: MU2008104/1170  
Office of Continuing Professional Development  
12901 Bruce B. Downs Blvd, MDC 46 • Tampa, FL 33612  
(813) 974-6304 • (813) 974-0162 (FAX)

**Pharmacists:**

The USF Health is accredited by the Accreditation Council for Pharmacy Education as a provider of continuing pharmacy education. This program has been approved for 1.5 contact hours. Universal program number is as follows: #230-999-08-009-H04-P. Phone number: (813) 974-6304.

**Release Date/Expiration Date:**

Release Date: November 1, 2008 • Expiration Date: October 31, 2010

**Disclaimer Statement:**

The information provided in this CME/CE activity is for continuing education purposes only and is not meant to substitute for the independent medical/clinical judgment of a healthcare provider relative to the diagnostic and treatment options of a specific patient's medical condition.



To receive continuing education credit, a pharmacist must review the materials on accreditation, information, target audience, learning objectives, and disclosure information; complete the entire self-study activity; complete the post-test assessment and evaluation/claim form; and mail/fax claim form to the appropriate address.

**Support:**

Support has been provided for this program by an educational grant from Sirion Therapeutics.

All Participants who are requesting Pharmacy Credit should expect to receive their statement of credit either on-site or within 4 weeks by U.S. Mail upon the conclusion of the activity.

**Nurses (ANCC):**

The University of South Florida College of Nursing is accredited as a provider

**Contact Information:**

For additional information about this or other CE programs please contact:  
Focus-ED • PO Box 82009 • Tampa, FL 33682 • (813) 988-7795

## INTRODUCTION

Herpetic keratitis is one of the leading causes of corneal opacification and infection-related vision loss in both the United States and the industrialized world.<sup>1,2,3</sup> It is also one of the primary indications for corneal transplantation in the United States.<sup>3</sup>

Ocular manifestations of herpetic keratitis are caused by two types of herpes infections, either herpes simplex virus (HSV) or herpes zoster (HZ). Worldwide, an estimated 10 million people have been affected by herpetic eye disease caused by HSV. In the United States alone HSV is responsible for approximately 20,000 new diagnoses and 28,000 reactivations annually.<sup>1,2,3,4,5</sup> Additionally, HZ is estimated to afflict up to 20% of the world population, and 10-20% of those cases will have ophthalmic involvement.

The diagnosis of herpetic keratitis can be difficult which can subsequently delay appropriate treatment. Some treatments can exacerbate the effects of herpetic keratitis if used inappropriately. Newer diagnostic methods and therapies can help to improve patient outcomes for this disease.

## HERPES SIMPLEX VIRUS-INDUCED HERPETIC KERATITIS

### Incidence, Prevalence, and Etiology.....

#### Incidence

Of the various strains of herpes simplex viruses, HSV-1 is the primary cause for ocular herpes infections. While ocular infections from HSV-2 are uncommon, they are generally a result of contact with infectious genital secretions. Initial episodes of herpetic keratitis may begin at any age and recurrence is common.<sup>6</sup>

In a study by Jabs, it was estimated that there are approximately 50,000 combined new and recurrent cases of ocular HSV disease annually in the United States.<sup>1,7</sup> The recurrence rate of ocular HSV infection increases as the length of time from the initial infection increases:<sup>8</sup>

- 20% at 2 years post-infection
- 40% at 5 years post-infection
- 67% at 7 years post-infection

Other herpetic keratitis studies conducted in Rochester, Minnesota by Liesegang et al found that the most common ocular presentation included involvement of the epithelium, occurring in 63% of cases. Involvement of the stroma was less common, with stromal keratitis occurring in 6% of cases.<sup>9</sup>

#### Prevalence

Most HSV infections are subclinical. Fifty to eighty percent of adults are seropositive for HSV-1, and 20-40% of adults are seropositive for HSV-2.<sup>8</sup> Herpes labialis (H. febrilis) affecting

the vermilion border of the lips is the most common form of recurrent HSV-1, but 30% of genital HSV is also derived from HSV-1 infection rather than the more common genital virus HSV-2.<sup>8</sup> It is estimated that throughout the world, more than 90% of humans have been exposed to HSV-1 and are seropositive for it before age 50.<sup>10,11</sup> Seropositivity may underestimate true infection rate however. Recent studies show that more than 95% of adults shed HSV-1 DNA in the tears and saliva. Additionally, studies of cadavers show similar rates of HSV-1 positivity by polymerase chain reaction (PCR) in the trigeminal ganglia.

### Etiology

Recurrent ocular HSV infection is considered a reactivation of the HSV virus previously lying dormant in the trigeminal ganglion. HSV may migrate down the nerve axon to produce a lytic infection in ocular tissue. Often, patients develop an ensuing ocular disease without ever having had a primary ocular HSV infection.<sup>3</sup> Evidence also suggests that the virus may exist latently within corneal tissue, serving as another potential source of recurrent disease.<sup>12</sup> Immune-suppression may have a role in activating herpes infections.<sup>13</sup> However, theories of latent corneal HSV infection as a cause of recurrent disease continue to be controversial.<sup>3</sup>

### Symptoms.....

Patients with ocular herpes simplex manifestations may present with the following complaints:<sup>3,8</sup>

- Corneal pain
- Foreign body sensation
- Photophobia
- Blurred vision
- Lacrimation
- Redness around the eyes, forehead, and possibly, the nose
- Corneal ulceration with or without dendritic branching

Herpetic keratitis is typically unilateral but can also be bilateral.<sup>14</sup> Ocular HSV can also manifest as a post-surgical adverse effect (e.g., cataract, LASIK, corneal transplantation) even in patients without a prior history of HSV.<sup>15,16</sup> [Post-operative management will be covered in a future issue of Ocular Inflammation & Infection, Volume 1.]

HSV-1 infections can vary either because the virus is genetically variable or because host resistance varies. Various isolates of HSV-1 will cause large, medium or small dendrites. HSV-1 DNA that creates epithelial disease is different from HSV-1 DNA causing stromal disease. The tendency for recurrences appears to be a property of the particular genetic composition of the virus.

### Diagnosis.....

A clinical diagnosis of HSV keratitis is primarily obtained due

to characteristic features of the corneal lesion.<sup>3</sup> HSV keratitis is most often a manifestation of subclinical infection. Primary herpetic keratitis is rare and is usually preceded by unilateral blepharoconjunctivitis, which is characterized by vesicles on the skin of the lids, follicular conjunctivitis, and preauricular adenopathy.<sup>11</sup>

Diagnostic tests may confirm infection in some cases lacking typical findings, but they are not readily available in all clinical settings. One easily obtainable test is HerpChekTM (DuPont), an enzyme immunoassay (EIA) that can be conducted in a clinic or office. Other laboratory procedures that may confirm a diagnosis of HSV keratitis and are typically available in an outside commercial laboratory are listed in Table 1.

**Table 1.**  
**Laboratory Procedures to Diagnose HSV Keratitis.**<sup>3, 17, 18, 19, 20</sup>

<b>Viral Culture</b>	High sensitivity/specificity when culture is obtained within several days of onset; identifies HSV subtypes	108 hours for positive results; 154 hours for negative results
<b>ELVIS</b>	Enzyme-linked viral inducible system is sensitive and specific; with a negative test result, cell culture is recommended to confirm HSV	24 hours
<b>Polymerase Chain Reaction</b>	PCR allows detection of HSV 1 & 2 DNA from a viral swab; more sensitive than both cell culture and EIA; does not distinguish between latent or active HSV infection; detects only the target virus; does not yield an isolate for further testing	24 hours

### Classification

HSV keratitis may be divided into 4 categories:<sup>3</sup>

- infectious epithelial keratitis
- metaherpetic keratopathy
- stromal keratitis
- endotheliitis

### Infectious Epithelial Keratitis

Infectious epithelial keratitis, the most common ocular HSV disease, is a result of an active infection of the corneal epithelium.<sup>3,10</sup> In a long-term study conducted by Jabs, epithelial involvement was the most common ocular symptom of infectious epithelial keratitis, occurring in 63% of episodes.<sup>1</sup> It is characterized by vesicles, dendritic ulcers, and geographic ulcers. Although the vesicles are the earliest sign of active viral replication in the corneal epithelium, they are rarely seen during a patient's first presentation. Patients with a history of HSV keratitis may develop vesicles without presenting any clinical symptoms.<sup>3</sup>

A dendritic ulcer results from the coalescence of corneal vesicles. It is the most common presenting symptom of HSV keratitis.<sup>3</sup> While the dendritic ulcer is active, it shows a positive fluorescein staining. The ulcer's branching terminal bulbs, linear shape, and swollen epithelial border stain brightly with fluorescein, and its edges can be stained with Rose Bengal or lissamine green.<sup>3,10</sup> When it is healing, the dendriform-shaped epithelium is slightly raised and shows negative fluorescein staining as the fluorescein forms a border around the ulcer.<sup>10</sup>

A geographic ulcer results when the infectious ulcer enlarges and the shape is no longer linear. The scalloped or geographic borders of a geographic ulcer distinguish it from the smooth borders of a metaherpetic ulcer.<sup>3,10</sup> These manifestations are due to multiplying virus and can benefit from antiviral therapy.

### Metaherpetic Keratopathy

A non-infectious ulcer can occur with stromal damage caused by a previous infection. Metaherpetic keratitis results from an inadequate healing process rather than an active herpes infection. It is characterized by impaired healing of the corneal epithelium as a result of interrupted innervation and decreased tear formation, or by damage to the stroma over which the epithelium must heal.<sup>3,10,21</sup> This is commonly seen in patients with repeated HSV infectious epithelial keratitis and/or HSV disciform endotheliitis. Healing problems can also result from damage to the basement membrane and stroma during a previous infection episode.<sup>3,6,10</sup> Long-term use of topical antivirals can exacerbate this condition.<sup>3,10,21</sup>

Early signs of metaherpetic keratopathy include irregular patches on the corneal surface, reduction in corneal luster, and punctate epithelial erosions.<sup>6</sup> These erosions may advance to form a persistent epithelial defect, which can ulcerate into the stroma and develop a gray-white opacification.<sup>3,10,11</sup>

A metaherpetic ulcer is generally oval-shaped with smooth borders and commonly lies within the interpalpebral fissures, located in the central or inferior paracentral corneal area. Complications of metaherpetic keratopathy include stromal scarring, neovascularization, necrosis, and perforation.<sup>3</sup>

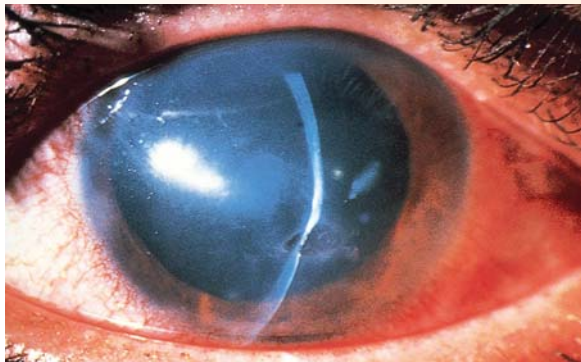
Unpreserved lubricants eyelid patching, bandage contact lenses, and autologous serum may be used in the management of metaherpetic keratopathy.<sup>3</sup> Topical antivirals are of little value in the absence of multiplying virus and may be toxic. If metaherpetic keratitis is suspected, but the absence of virus is uncertain, oral antivirals such as acyclovir can be given. The drug will be secreted into the tears to minimize ocular toxicity.

**Stromal Keratitis**

Stromal keratitis, involving the deeper layers of the cornea, can result in corneal scarring and loss of vision.<sup>1</sup> Stromal keratitis develops in 25% of patients with epithelial disease.<sup>11</sup> The two primary forms of stromal involvement are presented in Table 2.

Recurring episodes often result in the need for a corneal transplant. While corneal stromal inflammation may be a primary symptom of herpetic keratitis, it can also occur secondary to infectious epithelial keratitis, metaherpetic keratopathy, or endotheliitis.<sup>3</sup>

Destructive intrastromal inflammation created by necrotizing stromal keratitis can cause thinning and perforation within a



*Chronic sequelae of herpes simplex virus stromal keratitis. Taken from: Chodosh J, Atlas of Ophthalmology. Edited by Richard Parrish II, Richard K. Forster. Philadelphia, Current Medicine Group LLC, ©2000.*

short period of time.<sup>3,10</sup> A possible risk factor for this development includes the use of topical corticosteroids without antiviral coverage.<sup>3,11</sup> Immune stromal keratitis attacks the inner layers of the cornea and can result in stromal scarring or disciform edema.<sup>7</sup>

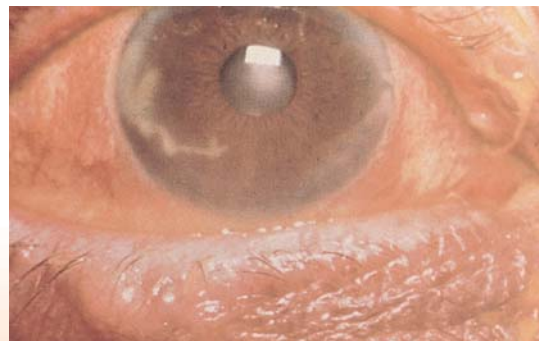Topical corticosteroids with antiviral coverage may be used to treat anterior stromal inflammation.<sup>6</sup> Ulcers that do not respond to these measures may heal with tarsorrhaphy.<sup>3</sup> Rigid gas-permeable contact lenses may be used to correct irregular astigmatism resulting from chronic stromal keratitis in spite of a small additional risk of recurrence.<sup>6</sup> A small descemetocele or perforation in an inflamed eye may be managed initially with tissue adhesive and a bandage contact lens.<sup>11</sup>

**Table 2.**  
**Primary Forms of Stromal Keratitis.**<sup>3,10,11</sup>

Form	Etiology	Symptom
<b>Necrotizing Stromal Keratitis</b>	Viral replication in stromal keratocytes and severe host inflammatory response	Dense stromal infiltrate, ulceration, and necrosis; may resemble bacterial or fungal keratitis
<b>Immune Stromal Keratitis</b>	Antibody-complement cascade that reacts to a viral antigen within the stroma	Subepithelial haze and scarring; stromal inflammation; focal, multifocal, or diffuse cellular infiltrates; immune rings; stromal infiltration with or without neovascularization; ghost vessels at any level of the cornea

**Endotheliitis**

Endotheliitis is characterized by keratic precipitates (KP), overlying stromal and epithelial edema, and absence of stroma infiltrate or neovascularization.<sup>3</sup> While it has been primarily considered an immunologic reaction to an antigen in endothelial cells, speculation exists regarding the role of a live virus.<sup>3</sup> Endotheliitis may occur several months to years following an episode of infectious keratitis.<sup>11</sup> According to the Jabs study, intraocular inflammation involvement (iritis or uveitis) occurred in 4 % of ocular herpetic disease episodes.<sup>1</sup>



*Conjunctivitis with a dendritic corneal ulceration due to HSV. Taken from: Margileth A, Atlas of Infectious Diseases: Upper Respiratory and Head and Neck Infections, Edited by Gerald Mandell (series editor), Itzhak Brook. Philadelphia, Current Medicine Group LLC, ©2000.*

Inflammation directed at the endothelium may cause endothelial decompensation and overlying stromal and epithelial edema.<sup>3</sup> Three classifications of endotheliitis are presented in Table 3.

**Table 3. Classifications of Endotheliitis.**<sup>3,11</sup>

Classification	Symptom
<b>Disciform</b>	A round area of corneal edema in a central or paracentral region, overlying an area of KP, with a clear demarcation between involved and uninvolved cornea
<b>Diffuse</b>	Scattered KP and diffuse edema; may stem from a previous disciform area of involvement
<b>Linear</b>	A sectoral or circumferential line of KP progressing centrally from the limbus; associated corneal edema is isolated to the peripheral corneal stroma and epithelium; may appear as either a straight pattern or a more slowly spreading pattern

Disciform edema and diffuse edema are usually treated successfully with corticosteroids. Incisional or laser corneal refractive surgery can reactivate HSV keratitis, and are considered a relative contraindication for those with inactive keratitis or a history of HSV disease. Case reports have documented that preoperative systemic antivirals can prevent reactivation of HSV following refractive surgery.<sup>3</sup>

Contact lens wear should be reserved for an optical benefit rather than for cosmetic purposes. Patients should know that wearing contact lenses can lead to an increase in the risk of secondary infection with HSV epithelial keratitis. Patients should discontinue wearing contact lenses at the earliest symptoms of a recurrence of HSV keratitis.<sup>3</sup>

### Treatment

Treatment guidelines for herpetic keratitis have been proposed by various authors but have not been universally accepted. Considering the potentially disabling consequences of infectious keratitis, immediate ophthalmic consultation is critical. As most episodes of HSV epithelial keratitis resolve spontaneously within three weeks, the primary treatment objective is to minimize stromal damage and scarring.<sup>3</sup>

### Antivirals

The National Institutes of Health's Herpetic Eye Disease Study Group (HEDS) organized several randomized, controlled clinical trials to evaluate oral antiviral therapy and topical steroid treatment for herpetic keratitis. Results of the HEDS studies changed standards of practice by demonstrating the following results:<sup>10,7,14</sup>

- Oral acyclovir (400 mg bid) used to treat stromal disease and iritis were not of any benefit.
- A prophylactic three-week course of oral acyclovir was of no benefit in stopping the progression of herpes epithelial disease to stromal disease.
- Patients on oral acyclovir had a 41% reduction in recurrence rates of all forms of ocular HSV infection.
- Oral acyclovir reduced recurrences of HSV stromal keratitis by 50% as long as therapy was continued. There is no benefit once it is discontinued.
- Prednisolone steroid treatment, in conjunction with an antiviral treatment, benefited acute disease with no detriment during a six month follow-up.

The HEDS data suggested that patients who have had a recurrence, especially multiple recurrences, have a higher risk for additional recurrences. During a recurrent episode, the average length of active disease was 28.4 days and the average number of visits to an ophthalmologist was 5.9 per episode.<sup>1</sup> Given the documented reduction in recurrence provided by oral acyclovir, the HEDS findings suggest that the economic influence of HSV keratitis would decrease with prophylactic acyclovir therapy in patients with frequent stromal recurrences.<sup>1</sup> The risks of long-term therapy may outweigh the benefits in patients with epithelial disease.

The reduction of recurrences of stromal keratitis with acyclovir suggests that viral replication does have a role in stromal keratitis, although the comparative contributions of viral replication and the immune response have yet to be established.<sup>1</sup> One reason why oral acyclovir provides incomplete protection from recurrence is that viral spreading and shed do occur. Surface HSV infection can be inhibited but not HSV infection within the ganglia.<sup>1</sup>

Topical antiviral agents are the current treatment of choice for treating HSV-induced herpetic keratitis. The specific regimen is based on manifestations and severity of the disease. They can be started in the absence of a confirmatory HSV culture or antigen as a protective measure.<sup>22, 37</sup>

Topical trifluridine (trifluorothymidine, TFT, Viroptic®, Monarch Pharmaceuticals) 1 % drops are often used 9 times daily to treat epithelial herpes.<sup>11</sup> TFT therapy usually results in 97% healing within two weeks if no other aggravating factors are present. An antiviral derivative of thymidine, TFT becomes incorporated into the DNA of both the virus and

healthy cells leading to epithelial toxicity.<sup>23</sup> Long-term treatment should be done under observation to monitor cytotoxicity.<sup>22</sup>

An alternative treatment for herpetic keratitis is acyclovir topical ointment (Zovirax® 5%, GlaxoSmithKline, generic) that is typically started five times daily with the dosage tapering off once the healing process is obvious. Acyclovir ointment has been used in Europe with some efficacy. However, patients have not readily adopted this treatment due to blurred vision and discomfort from the ointment.<sup>23</sup>

Other antivirals related to acyclovir are also used to treat herpetic keratitis. Valacyclovir (Valtrex®, GlaxoSmithKline) is an oral prodrug that converts to the active drug acyclovir to lessen the symptoms of HSV keratitis.<sup>3</sup> It is preferred over oral acyclovir since its improved absorption is much more reliable in producing higher blood concentrations. Although the initial cost is more expensive than oral acyclovir, fewer doses are required, thereby making absolute treatment costs comparable. It may be used in conjunction with a bandage lens and unpreserved tears to treat late stage ulcers. It also offers an alternative or adjunct for those patients who have difficulties taking drops, such as children. Valacyclovir is also a drug of choice for frequent recurrences or long-term treatment due to its favorable safety profile.<sup>24</sup>

Famciclovir (Famvir®, Novartis Pharmaceutical) is an oral guanine analog prodrug that is converted into penciclovir, an active metabolite. It is an effective alternative to oral acyclovir or valacyclovir for treatment of HSV and varicella zoster virus (VZV) infections.<sup>25</sup> While it may reduce viral DNA production and replication, its effectiveness in treating HSV keratitis has not been studied.<sup>3</sup>

Ganciclovir also inhibits HSV infections and replication by a pharmacologic mechanism similar to acyclovir. Topical ganciclovir is available in an aqueous gel-formulation. Its ocular distribution is similar to tears allowing homogeneous distribution over the eye with prolonged retention. This formulation improves tolerability in regards to stinging or burning sensations and visual disturbances when compared to acyclovir ointment.<sup>23</sup> Four herpetic keratitis clinical trials with ganciclovir gel were conducted on patients with dendritic or geographic ulcers. Patients were initially treated with either ganciclovir gel or acyclovir ointment five times a day. Ganciclovir triphosphate concentration in the cell can be 10-fold higher than that of acyclovir triphosphate and decline more slowly.<sup>23</sup> Each study concluded that ganciclovir 0.15% topical gel was at least as effective as acyclovir 3% ointment with improved tolerability.<sup>23</sup> In addition, ganciclovir gel is selective for the herpes virus when compared to TFT. It does not inhibit host cellular DNA synthesis as TFT does and is therefore expected to have a superior safety profile.<sup>23</sup> In initial studies, ganciclovir and TFT act synergistically which could potentially result in a more effective treatment option

in the future.<sup>14</sup>

Ganciclovir gel is a first line therapy for the treatment of acute superficial herpetic keratitis in Europe where it has been available for more than 10 years. In April 2007 it achieved orphan drug designation in the United States and is expected to be approved in the United States in 2008 for the treatment of herpes simplex keratitis.<sup>26</sup>

Another potential future treatment is an antiviral that is a helicase-primase inhibitor. The mechanism of action differs from the previous antivirals in that it prevents double-stranded viral DNA from multiplying. Additional research could possibly demonstrate superior effectiveness and safety to current herpetic keratitis treatments.

### **Corticosteroids**

The HEDS trial demonstrated that steroids can be effective in treating acute herpetic keratitis. Corticosteroid administration for disciform keratitis and stromal disease improved results with no apparent adverse consequences during treatment or during six months follow-up after therapy.<sup>27</sup>

A combination of corticosteroid and antiviral therapy can be used to treat stromal keratitis and endotheliitis. Initially, frequent topical steroid therapy is prescribed along with antiviral medication to prevent or limit lytic epithelial keratitis. One regimen uses a topical antiviral agent and a corticosteroid with equivalent frequency (beginning with 4x/day) until the steroid dosage can be reduced to a once-daily or less (at least 3 months). For a patient with necrotizing stromal keratitis, a systemic antiviral is preferred due to concerns regarding corneal toxicity.<sup>3</sup> Recurring stromal disease may be treated with corticosteroids as long as the disease is active but premature cessation can cause additional scarring. A minimal dose should be for at least 3 months adding an oral antiviral once the disease becomes inactive.<sup>14</sup>

### **Surgical Options**

Corneal surgery to correct scarring and aberrations from herpetic keratitis can be scheduled once a patient has been asymptomatic for a few weeks.<sup>14</sup>

### **Keratoplasty**

Penetrating keratoplasty (PKP) for visual restoration may be indicated in a patient presenting with:<sup>3,6,11</sup>

- Visually significant corneal opacity, stromal thinning, or corneal perforation
- Corneal scarring that reduces vision considerably
- Formation of descemetocele
- Continual inflammation that is non-responsive to treatment

In eyes that are clear of inflammation prior to surgery, the prognosis for a successful graft is up to 80%.<sup>3</sup> Use of a pro-

prophylactic antiviral therapy for 12 months following PKP may decrease the recurrence rate of HSV dendritic keratitis and may also improve graft survival.<sup>3,11</sup> In rare cases of failed PKP, the Dohlman keratoprosthesis may be used to restore vision with a reasonable opportunity for success.<sup>28</sup>

Theories of latent corneal HSV infection as a cause of recurrent disease continue to be controversial.<sup>3</sup> Graham and Assil note that the rate of recurrent herpetic keratitis following PKP remains unchanged because the recurrence is the result of reactivation of latent virus in the nerve ganglion.<sup>11</sup>

### Phototherapeutic Keratectomy/ Photorefractive Keratectomy

The excimer laser is used in phototherapeutic keratectomy (PTK), or Photorefractive Keratectomy, a novel modality in the treatment of a number of superficial corneal disorders including superficial scars. This is used alone or as an adjunctive strategy in traditional corneal surgical techniques. A correction can also be programmed into the laser to provide optical correction. Prophylactic oral acyclovir or valacyclovir (500 mg bid) should be given at least two days prior to the procedure and continued for at least two weeks following treatment.<sup>14,29</sup>

### Photorefractive Keratectomy

Photorefractive keratectomy (PRK) is another refractive surgery that can be used to treat herpetic keratitis. The excimer laser used in PRK utilizes a cool ultraviolet light beam to precisely ablate very tiny bits of tissue from the corneal surface in order to reshape it. This may be preferred for patients with larger pupils or thin corneas.<sup>37</sup> For patients with slight superficial scarring from herpetic keratitis, PRK can remove the scar and correct the refractive error. Prophylactic oral acyclovir or valacyclovir (500 mg bid) should be given at least two days prior to the procedure and continued for at least two weeks following treatment.<sup>14,30</sup>

## HERPES ZOSTER VIRUS-INDUCED HERPETIC KERATITIS

### Incidence, Prevalence, and Etiology

Annually, the incidence of herpes zoster (HZ), also known as shingles, is approximately 1.5 to 4.0 cases per 1000 persons; with up to 1 million or more cases annually in the United States.<sup>31,32</sup> While the incidence of HZ is comparatively low in younger people, the incidence increases greatly after age 50.<sup>33</sup> According to the U.S. Census Bureau's 2006 population estimates, over 37.2 million people in the United States were older than 65. As many as 50% of those living to age 85 will have had HZ at some time in their lives.<sup>31,33</sup>

The varicella-zoster virus (VZV), also known as human herpes virus type 3, manifests itself in two distinct diseases. A primary

infection results in chickenpox, commonly seen in childhood. A rash of blister-like lesions can cover the body but usually is more concentrated on the face, scalp, and trunk. Fever may develop just before or when the rash appears. Recurrences are rare. Mild conjunctivitis or episcleritis may be present. Rarely iritis, microdendritic keratitis, disciform keratitis, sclerokeratitis, or mucous plaque keratitis occur. Innoculation with the vaccine almost always prevents severe symptoms.<sup>34</sup>

In adulthood, HZ results from prior exposure to wild-type or vaccination-type VZV infection. It typically produces a prodrome of malaise, headache, and fever, followed by rash and unilateral pain in a dermatomal distribution. HZ occurs usually in older adults as a result of reactivation of latent VZV infection as confirmed by DNA studies.<sup>5</sup>

Over 90% of adults in the United States are at risk for herpes zoster and have serologic evidence of VZV infection.<sup>32</sup> The incidence of HZ is expected to continue increasing in the future due to the increasing number of older Americans combined with increasing exposure to the childhood varicella vaccine.

Ocular manifestations of HZ caused by VZV are referred to as herpes zoster ophthalmicus (HZO). HZO involves the nerve that supplies the skin around the scalp, forehead, and upper eyelid. Corneal complications, including epithelial keratitis, dendritiform lesions, corneal edema, and neurotrophic ulcers result in nearly 65% of patients with HZO.<sup>6</sup> Uveitis occurs in nearly 40% of HZO cases.<sup>35</sup>

### Symptoms

Patients with HZO typically present with the following complaints:<sup>6,31,32,35</sup>

- Corneal pain typically in one eye only
- Swelling and cloudiness of the cornea creating blurred vision
- Unilateral redness of the eye and around the eyes, forehead, and possibly, the nose
- Pain or tingling feelings on one side of the scalp, forehead, and face
- Cutaneous vesicular lesions that present on the forehead
- Headache, chills, malaise, and fever
- Lesions on the tip of the nose

Post-herpetic neuralgia can persist for years requiring pain control with strong opiates. The pain can be so severe as to be a cause of suicide.

## Diagnosis

A clinical diagnosis of herpes zoster is often accurate due to its characteristic appearance, presence of a unilateral blistering rash that does not cross the midline with accompanying pain, and its involvement with the scalp, forehead, and upper eyelid.<sup>32, 35</sup> Laboratory confirmation may be required if the location or appearance of lesions is uncharacteristic. The following are other diagnostic options for HZO:<sup>36</sup>

- A fluorescein application may be used to detect lesions on the corneal epithelium
- Rose Bengal may be used to distinguish dendritiform lesions from HSV keratitis dendrites
- A Tzanck smear and Wright stain could be performed to reveal herpes virus infections (these tests do not differentiate VZV from other herpes viruses)
- A viral culture could be obtained, although the virus is fairly challenging to recover from the scrapes
- A direct immunofluorescence assay can differentiate herpes simplex virus infections from VZV infections.
- Polymerase chain reaction techniques can be useful in detecting the virus DNA from the lesions

## Treatment

### Antivirals

In the United States, three oral antivirals have been approved for treating HZ: acyclovir, valacyclovir, and famciclovir. Without implementing antiviral therapy, nearly 50% of patients with HZ develop HZO.<sup>5,32</sup> Implementing antiviral therapy may reduce the frequency of late ocular complications from approximately 50% in untreated patients to 20-30% in treated patients.<sup>32,36</sup>

The treatment of choice is oral valacyclovir administered at a dosage of 1000 mg taken three times daily for 7 days. Preferred for its reliable absorption, valacyclovir produces serum acyclovir levels that are 3-5 times higher than levels achieved during oral acyclovir therapy.<sup>36</sup> In a randomized trial of patients at least 50 years of age, valacyclovir notably reduced the median time to HZ-associated pain resolution.<sup>32</sup>

Evidence suggests that longer activity of the VZV on the cornea or in the central nervous system may require more prolonged antiviral regimens, particularly in immunocompromised or older patients.<sup>5</sup>

### Corticosteroids

The use of corticosteroids in combination with acyclovir has been studied in two large, controlled clinical trials.

Combining these therapies produced a statistically significant decrease in acute pain and increase in the cutaneous healing rate. Trial participants also reported improved quality of life measured by analgesic use, uninterrupted sleep time, and the amount of time required to return to their usual activities.<sup>32</sup> Corticosteroid use with valacyclovir or famciclovir has not been studied, although these combinations are presumed to be equally as effective.

Use of steroid eye drops may benefit certain ocular diseases, but can exacerbate other diseases. Table 4 lists ocular complications due to HZO and their recommended treatments.

**Table 4. Recommended Treatments for HZO-related Ocular Complications<sup>36</sup>**

Complication	Recommended Drug Treatment
Blepharitis; Conjunctivitis	Topical antibiotics for secondary infections
Stromal Keratitis	Topical steroids
Metaherpetic Keratitis	Topical antibiotics for secondary infections
Uveitis	Topical steroids; oral steroids; oral acyclovir; cycloplegics
Scleritis; Episcleritis	Topical nonsteroidal anti-inflammatory agents and/or steroids
Acute Retinal Necrosis; Progressive Outer Retinal Necrosis	Intravenous acyclovir followed by oral acyclovir

## Surgery

Corneal scarring often remains following VZV infection. Lamellar keratoplasty or keratectomy has proven useful in removing corneal scarring. Excimer laser phototherapeutic keratectomy (PTK) and microkeratomes may be used, as well as LASIK surgery.<sup>5</sup> Published articles, on studies regarding postherpetic scar treatment by PTK, present conflicting results.

## Prevention .....

A review of data from the Shingles Prevention Study found that the herpes zoster vaccine was safe, well-tolerated, and effective in reducing illness and complications due to HZ. A vaccination of a high-titer, live, attenuated zoster virus was related to more than a 50% reduction in the overall incidence of HZ. Subjects that did develop HZ demonstrated a decrease in pain and discomfort.<sup>33</sup>

The vaccine is commercially available (Zostavax<sup>®</sup>, Merck) for protection of adults against herpes zoster. It contains a higher dosage of virus than the "chickenpox vaccine" for children.<sup>31</sup> The difference in the titer is required to obtain a significant and long-lasting increase in the cell-mediated immunity in adults over 60 years of age.<sup>31,33</sup> The vaccine is recommended by the Centers for Disease Control and the Prevention Advisory Committee on Immunization Practices (ACIP) for persons age 60 and over to prevent HZ; including for those patients who have had an outbreak of HZ.<sup>34</sup>

## SUMMARY .....

No cure currently exists for herpetic keratitis although some treatments can ameliorate its effects and recurrences. Untreated or mistreated herpetic keratitis has the potential of debilitating consequences and loss of vision. As the population expands and ages, the prevalence of ocular HSV and HZ infections increases. Health care professionals must be increasingly vigilant of the signs and symptoms of herpetic keratitis, referral and diagnostic options, and appropriate treatments. Zostavax should be recommended to people over the age of 60 to reduce their risk of HZ. Further research on pharmaceutical agents involving new mechanisms of action or more effective treatment options in the future.

## References

1. Jabs, D. A. (1998). Acyclovir for recurrent herpes simplex virus ocular disease [Editorial]. *The New England Journal of Medicine*, 339(5), 340-341.
2. Herpetic Eye Disease Study Group. (1998). Acyclovir for the prevention of recurrent herpes simplex virus eye disease. *The New England Journal of Medicine*, 339, 300-306.
3. Wang, J. C. (2007). Herpes simplex keratitis. *emedicine Specialties*, Retrieved March 16, 2008, from <http://www.emedicine.com/ophthalmology/index.shtml>
4. Herpetic Eye Disease Study Group. (2000). Oral acyclovir for herpes simplex virus eye disease. *Archives of Ophthalmology*, 118, 1030-1036.
5. Kaufman, H. E. (Ed.). (2008, February). Herpes zoster ophthalmicus: Preventing ocular complications through vaccination. Supplement to *Ophthalmology*, 115(2), S1-38.
6. Calderon, D., & Schinas, Z. (2005). Vanquish the virus: There are many ocular manifestations of herpetic eye disease. *Review of Optometry*. Retrieved April 2, 2008, from <http://www.revoptom.com/index.asp?ArticleType=SiteSpec&page=osc/10210/lesson.htm>
7. National Institutes of Health. (1998). *Antiviral drug sharply reduces return of herpes of the eye*. Retrieved May 14, 2008, from [www.scienceblog.com](http://www.scienceblog.com)
8. Hynes, N. A. (2007). Herpes simplex virus. *John Hopkins POC-IT Center ABX Guide*. Retrieved March 30, 2008, from [http://prod.hopkins-abxguide.org/pathogens/viruses/herpes\\_simplex\\_virus.html?contentInstanceId=255988](http://prod.hopkins-abxguide.org/pathogens/viruses/herpes_simplex_virus.html?contentInstanceId=255988)
9. Liesegang, T. J., Melton, L. J., Daly, P. J., & Ilstrup, D. M. (1989). Epidemiology of ocular herpes simplex: incidence in Rochester, Minn, 1950 through 1982. *Archives of Ophthalmology*, 107(8):1155-9.
10. Jun, W. (2006). *A review of ocular infections caused by herpes simplex virus*. Retrieved March 26, 2008, from Pacific University, College of Optometry Web site: <http://opt.pacificu.edu/ce/catalog/14382-AS/Herpes.html>
11. Graham, R.H. & Assil K. (2006). Herpes simplex. *Emedicine*. Retrieved April 4, 2008, from <http://www.emedicine.com/oph/TOPIC256.HTM>
12. Akkarawongsa, R., Cullinan, A. E., Zinkel, A., Clarin, J., & Brandt, C. R. (2006). Corneal toxicity of cell-penetrating peptides that inhibit herpes simplex virus entry. *Journal of Ocular Pharmacology and Therapeutics*, 22(4), 279-289.
13. Whitley, R. J., & Roizman, B. (2002). Herpes simplex viruses: Is a vaccine tenable? *The Journal of Clinical Investigation*, 110(2), 145-151.
14. Hovanesian, J. A., & Kaufman, H. K. (2008). *State of the art: Treatment prospects for herpes simplex disease*. Retrieved May 13, 2008, from [www.osnsupersite.com](http://www.osnsupersite.com)
15. Tullo, A. (2003). Pathogenesis and management of herpes simplex virus keratitis. *Eye*, 17, 919-922.
16. Barequet, I. S., & Wasserzug, Y. (2007). Herpes simplex keratitis after cataract surgery. *Cornea*, 26(5), 615-617.
17. Marshall, D. S., Linfert, D. R., Draghi, A., McCarter, Y. S., & Tsongalis, G. J. (2001). Identification of herpes simplex virus genital infection: Comparison of a multiplex PCR assay and traditional viral isolation techniques. *Modern Pathology*, 14(3), 152-156.
18. Kowalski, R. P., Karenchak, L. M., Shah, C., & Gordon, J. S. (2002). ELVIS: A new 24-hour culture test for detecting herpes simplex virus from ocular samples. *Archives of Ophthalmology*, 120, 960-962.
19. Onofrey, B. E., Skorin, L., Jr., & Holdeman, N. R. (2005). *Ocular therapeutics handbook: A clinical manual*. Philadelphia: Lippincott Williams & Wilkins.
20. *Herpes diagnosis*. (n.d.). Retrieved April 21, 2008, from <http://www.herpesdiagnosis.com/diagnose.html>
21. Neurotrophic keratitis. (2005, March 15). *Supplement to Review of Optometry*, 142, 26A-26A.
22. Anand, B. S., Hill, J. M., Dey, S., Maruyama, K., Bhattacharjee, P. S., Myles, M. E., Nashed, Y. E., & Mitra, A. K. (2003). In vivo antiviral efficacy of a dipeptide acyclovir prodrug, val-val-acyclovir, against HSV-1 epithelial and stromal keratitis in the rabbit eye model. *Investigative Ophthalmology & Visual Science*, 44(6), 2529-2534.
23. Colin, J. (2007). Ganciclovir ophthalmic gel, 0.15%: A valuable tool for treating ocular herpes. *Clinical Ophthalmology*, 1(4), 441-453.
24. Pham, P. A., & Bartlett, J. G. (2007). *Valacyclovir*. Retrieved April 13, 2008, from <http://prod.hopkins-abxguide.org/antibiotics/antiviral/valacyclovir.html?contentInstanceId=267265&siteId=153>
25. Pham, P. A., & Bartlett, J. G. (2007). *Famciclovir*. Retrieved April 13, 2008, from <http://prod.hopkinsabxguide.org/antibiotics/antiviral/famciclovir.html?contentInstanceId=267124&siteId=153>
26. Bartlett, J. D. (Ed.). (2008). *Ophthalmic drug facts* (19th ed.). St. Louis: Wolters Kluwer Health.
27. Herpetic Eye Disease Study Group. (1994). A controlled trial of topical corticosteroids for herpes-simplex stromal keratitis. *Ophthalmology*, 101(12), 1883-1895.
28. Aquavella, J. V., Qian, Y., McCormick, G. J., & Palakuru, J. R. (2006). Keratoprosthesis: Current techniques. *Cornea*, 25(6), 656-662.
29. Cornea & Laser Eye Institute. (n.d.). *Procedures and techniques*. Retrieved April 21, 2008, from <http://www.vision-institute.com/techniques/index.html>
30. Cornea & Laser Eye Institute. (n.d.). *Procedures and techniques*. Retrieved April 21, 2008, from <http://www.vision-institute.com/techniques/index.html>
31. Kimberlin, D. W., & Whitley, R. J. (2007). Varicella-zoster vaccine for the prevention of herpes zoster. *The New England Journal of Medicine*, 356(13), 1338-1343.
32. Gnann, J. W., & Whitley, R. J. (2002). Herpes zoster. *The New England Journal of Medicine*, 347(5), 340-346.
33. Burke, M. S. (2007). Herpes zoster vaccine: Clinical trial evidence and implications for medical practice. Supplement to *The Journal of the American Osteopathic Association*, 107(3), S14-S18.
34. Varicella (chickenpox) vaccination. (2007). *Centers for Disease Control and Prevention*. Retrieved April 10, 2008, from [www.cdc.gov/vaccines/vpd-vac/varicella](http://www.cdc.gov/vaccines/vpd-vac/varicella)
35. Hall, A. J. H. (2003, March). Herpes zoster ophthalmicus. *American Uveitis Society*. Retrieved April 12, 2008, from <http://www.uveitisociety.org/pages/diseases/hzo.pdf>
36. Moon, C. H., & Silverberg, M. A. (2006). Herpes zoster ophthalmicus. *eMedicine Specialties*. Retrieved April 12, 2008, from <http://www.emedicine.com/emerg/topic249.htm#section~AuthorsandEditors>
37. Segre, L. & Slonim, C. (2007). PRK: the original laser eye surgery. Retrieved May 19, 2008, from [AllAboutVision.com](http://AllAboutVision.com).

## ACCREDITATION

### Target Audience:

General ophthalmologists  
Cornea specialists  
Pharmacists  
Nurses



### Physicians:

This activity has been planned and implemented in accordance with the Essential Areas and Policies of the Accreditation Council for Continuing Medical Education (ACCME) through the joint sponsorship of USF Health and Focus-ED. USF Health is accredited by the ACCME to provide continuing medical education for physicians.

USF Health designates this educational activity for a maximum of 1.5 *AMA PRA Category 1 Credits™*. Physicians should only claim credit commensurate with the extent of their participation in the activity.

### Pharmacists:

The USF Health is accredited by the Accreditation Council for Pharmacy Education as a provider of continuing pharmacy education. This program has been approved for 1.5 contact hours. Universal program number is as follows: #230-999-08-009-H04-P. Phone number (813) 974-6304.



To receive continuing education credit, a pharmacist must review the materials on accreditation, information, target audience, learning objectives, and disclosure information; complete the entire self-study activity; complete the post-test assessment and evaluation/claim form; and mail/fax claim form to the appropriate address.

All Participants who are requesting Pharmacy Credit should expect to receive their statement of credit either on-site or within 4 weeks by U.S. Mail upon the conclusion of the activity.

### Nurses (ANCC):

The University of South Florida College of Nursing is accredited as a provider of continuing nursing education by the American Nurses Credentialing Center's Commission on Accreditation. This activity is for 1.5 contact hours.

### Estimated Time:

This activity will take 90 minutes to complete. Successful completion is defined as a score of 80%.

### Fees:

No fee will be charged for this activity.

### CE credit:

To claim CE credit, individuals must complete Ocular Infection & Inflammation, Vol. 1, Issue 1, Herpetic Keratitis Post Test, and Program Evaluation Form. Mail or fax these and the CE Request Form to the address below postmarked by October 31, 2010 to:

Attn: MU2008104/1170  
Office of Continuing Professional Development  
12901 Bruce B. Downs Blvd, MDC 46  
Tampa, FL 33612  
(813) 974-6304  
(813) 974-0162(FAX)

### Release Date/Expiration Date:

Release Date: November 1, 2008  
Expiration Date: October 31, 2010

### Disclaimer Statement:

The information provided in this CME/CE activity is for continuing education purposes only and is not meant to substitute for the independent medical/clinical judgment of a healthcare provider relative to the diagnostic and treatment options of a specific patient's medical condition.

### Support:

Support has been provided for this program by an educational grant from Sirion Therapeutics.

### Contact Information:

For additional information about this or other CE programs please contact:

Focus-ED  
PO Box 82009  
Tampa, FL 33682  
(813) 988-7795

## POST-TEST

- 1) The primary cause of ocular herpes infection is:
  - a) herpes zoster
  - b) HSV-1
  - c) herpes labialis
  - d) HSV-2
- 2) The most common presentation of herpetic keratitis involves the:
  - a) stroma
  - b) epithelium
  - c) Bruch's membrane
  - d) endothelium
- 3) Primary herpetic keratitis is not characterized by:
  - a) follicular conjuction
  - b) preauricular adenopathy
  - c) vesicles on the skin of the lids
  - d) flashes of light
- 4) Which of the following diagnostic tests for HSV keratitis can easily be performed in a clinic or office:
  - a) ELVIS
  - b) PCR
  - c) HerpChek
  - d) Viral culture
- 5) Which of the following is not a classification of HSV keratitis?
  - a) exotheliitis
  - b) infectious epithelial keratitis
  - c) stromal keratitis
  - d) metaherpetic keratopathy
- 6) Early signs of metaherpetic keratitis do not include:
  - a) punctuate corneal erosions
  - b) patches on the corneal surface
  - c) astigmatism
  - d) reduction in corneal luster
- 7) HEDS data suggests that patients who have had one recurrence of HSV keratitis:
  - a) have lower risk for future recurrences
  - b) have no risk for future recurrences
  - c) will require keratoplasty
  - d) have higher risk for future recurrences
- 8) The current treatment of choice for HSV keratitis is:
  - a) corticosteroids
  - b) PKP
  - c) PRP
  - d) topical antivirals
- 9) What percentage of adults in the U.S. have serological evidence of VZV infection?
  - a) 40%
  - b) 60 %
  - c) 75%
  - d) 90%
- 10) The HZ vaccine is recommended to prevent HZ by the Centers for Disease Control for persons age:
  - a) 60 years and older
  - b) 70 years and older
  - c) 50 years and older
  - d) 50 years and younger

### Evaluation/Post-Test, Ocular Inflammation & Infection Vol. 1, Issue 1, Herpetic Keratitis. Program #MU2008/1170

This activity is provided by Focus-Ed and University of South Florida Office of Professional Continuing Education, which is accredited as a provider of continuing medical education, nursing continuing education and pharmacy continuing education. To receive 1.5 CME credits, Pharma credits or CEU nursing contact hours for this activity, read the newsletter, complete the post-test and general evaluation form within (two) years of the publication date, and send it to:

Attn: MU2008104/1170  
Office of Continuing Professional Development  
12901 Bruce B. Downs Blvd, MDC 46  
Tampa, FL 33612  
(813) 974-4296  
(813) 974-3217(FAX)

Please refer to [www.Focus-ED.net](http://www.Focus-ED.net) for credit updates or contact Focus-ED at (813) 988-7795 for additional information. No fee will be assessed for this complimentary continuing education activity. Successful completion is defined as a score of 80% or higher.

Participants who do not achieve a minimum score of 80% may retake the test within 30 days. Please allow a minimum of 3 weeks from date of receipt of post-test to receive your CE verification certificate. Requests for certificates less than 3 weeks from date of receipt may be assessed a \$10 rush fee. Please plan ahead and submit your post-test well in advance of deadlines for recertification and relicensure.

#### Objectives:

- 1) Recognize symptoms of herpetic keratitis
- 2) Perform appropriate clinical test to correctly diagnose herpetic keratitis
- 3) Compare & contrast risks and precautions of treatments for herpetic keratitis
- 4) Review evidence-based rationale behind current treatments for herpetic keratitis

### Registration Information and Evaluation Response Form

Name: \_\_\_\_\_

Home Address: \_\_\_\_\_

City: \_\_\_\_\_ State: \_\_\_\_\_ Zip Code: \_\_\_\_\_

Home Phone: \_\_\_\_\_ Work Phone: \_\_\_\_\_ Fax: \_\_\_\_\_

State of Licensure: \_\_\_\_\_ License #: \_\_\_\_\_ Exp. Date: \_\_\_\_\_

**Type of credit desired:**     CME     Nursing Contact Hours     Pharmacist

**Test response:** Circle the most appropriate response matching test question number and response number.

- |            |            |            |             |
|------------|------------|------------|-------------|
| 1. A B C D | 4. A B C D | 7. A B C D | 10. A B C D |
| 2. A B C D | 5. A B C D | 8. A B C D |             |
| 3. A B C D | 6. A B C D | 9. A B C D |             |

**General Evaluation:** Please use the scale below to evaluate this educational activity and objectives. Circle your response.

As a result of completing this offering, I am able to meet the following objectives.

	4 Strongly Agree	3 Agree	2 Disagree	1 Strongly Disagree
1. Recognize symptoms of herpetic keratitis	4	3	2	1
2. Perform appropriate clinical test to correctly diagnose herpetic keratitis	4	3	2	1
3. Compare & contrast risks and precautions of treatments for herpetic keratitis	4	3	2	1
4. Review evidence-based rationale behind current treatments for herpetic keratitis	4	3	2	1
5. Commitment to change	4	3	2	1
6. The content matches the objectives	4	3	2	1
7. Independent study was an effective teaching method	4	3	2	1
8. Is the article free of commercial bias?	4	3	2	1
9. The time required to complete this offering (in minutes) and take the test was	60	75	90	>90